

PHARMACOLOGY AND THERAPEUTICS

## TREATMENT OF SKIN AGING WITH TOPICAL ESTROGENS

JOLANTA B. SCHMIDT, M.D.,

MARTINA BINDER, M.D., GABRIELE DEMSCHIK, M.D.,

CHRISTIAN BIEGLMAYER, Ph.D., AND ANGELIKA REINER, M.D.

### Abstract

**Background.** The coincidence of climacteric symptoms and the beginning of skin aging suggests that estrogen deficiency may be a common and important factor in the perimenopausal woman. Often hormones have been considered important in endogenous aging of the skin, but their role has not been clearly defined. Therefore, we investigated, whether topical treatment of the skin with estrogen could reverse some of the changes in the aging skin.

**Materials and Methods.** The effects of 0.01% estradiol and 0.3% estriol compounds were compared in 59 preclimacteric women with skin aging symptoms. Monthly determinations of estradiol (E2), follicle-stimulating hormone (FSH), and prolactin (PRL) were done and the monthly clinical monitoring was supplemented by measurements of skin hydration by corneometry and profilometry. In 10 patients, skin biopsies were taken for immunohistochemical determination of collagen types I and III.

**Results.** After treatment for 6 months, elasticity and firmness of the skin had markedly improved and the wrinkle depth and pore sizes had decreased by 61 to 100% in both groups. Furthermore, skin moisture had increased and the measurement of wrinkles using skin profilometry, revealed significant, or even highly significant, decreases of wrinkle depth in the estradiol and the estriol groups, respectively. On immunohistochemistry, significant increases of Type III collagen labeling were combined with increased numbers of collagen fibers at the end of the treatment period. As to hormone levels, only those of PRL had increased significantly and no systemic hormonal side effects were noted.

From the Department of Dermatology, Division of Special and Environmental Dermatology, University of Vienna Medical School, Vienna, Austria; the Institute for Medical and Chemical Laboratory Diagnostics, Department of Hormone Analysis, University of Vienna, Vienna, Austria; and the Institute of Clinical Pathology, University of Vienna, Vienna, Austria.

Address for correspondence: Jolanta B. Schmidt, M.D., Department of Dermatology, Division of Special and Environmental Dermatology, University of Vienna Medical School, Währinger Gürtel 18–20, A-1090 Vienna, Austria.

**Conclusions.** Both estrogen compounds were found to be highly effective in preventing or treating skin aging in perimenopausal women, clinically, by measurement data, and by an increase in collagen Type III.

Int J Dermatol 1996; 35:669–674

Topical tretinoin was the first substance with which significant improvements of skin appearance<sup>1</sup> could be correlated with histologic and *in vitro* findings.<sup>2–4</sup> Tretinoin is a very effective agent against solar radiation-induced exogenous skin aging.<sup>5</sup> In contrast, so far no agents were found to be effective in endogenous aging. Although hormones often were considered as important factors in endogenous skin aging, the scientific background of a hormonal role in the aging processes of the skin still remains poor.

In gynecology, the therapeutic effects of topical estrogens on atrophy of the vaginal and vulvar epithelia have been well described for many years.<sup>6,7</sup> During the past years, estrogen supplementation of the climacteric woman has opened new aspects on the wide variability of estrogen effects in various tissues. Beneficial effects on serum cholesterol,<sup>8</sup> on vascular actions in context with the myocardial infarction rate,<sup>9</sup> and improvement and prevention of osteoporosis<sup>10</sup> are only some of the paragnecologic estrogenic effects.

In skin tissue—an active target site of estrogens as shown by estrogen receptor determinations<sup>11,12</sup>—estrogens increase vascularization and show effects at various levels of dermal tissue. Improvement of the structure of elastic fibers after use of estriol cream<sup>13</sup> has been described. Furthermore, increases of acid mucopolysaccharides and of hyaluronic acid<sup>14,15</sup> augment the dermal water content. Distinct trophic effects of estrogen compounds—and also of estriol—on vaginal atrophy by increasing the maturation index associated with an increase of the number of superficial epithelial cells, support the epithelial actions of estrogens.<sup>6,16</sup>

These actions of estrogens prompted us to investigate whether topical estrogen treatment of the skin could reverse aging symptoms in estrogen-deficient women. In a preliminary study, the effects of a 0.3% topical estriol compound on the facial skin of climacteric women had been investigated<sup>17</sup> and compared

with those of a 0.01% estradiol compound. In another study, the effects of topical estriol iontophoresis treatment were studied in atrophic acne scars and compared with those of tretinoin-iontophoresis.<sup>18</sup> Both studies showed promising results. In the first study, clinical effects were shown in 80 to 100% of the patients. For the acne scars, significant and persistent improvement was demonstrated in all cases.

These preliminary results encouraged us to extend the investigations of estrogen compounds on skin aging to a larger number of patients. Moreover, the clinical monitoring was substantiated by skin measurement data and by investigations of collagen antibodies using immunohistochemistry.

## Materials and Methods

**Patients:** Two groups of women volunteers with skin aging symptoms, who did not take hormonal supplements, were included in the study. All women were peri- or postmenopausal or had had a hysterectomy, three of them with an ovariectomy. Twenty-eight women with a mean age of 54 years (range 43–66 years) were treated with a 0.01% estradiol compound. Thirty women with a mean age of 53 years (range 41–67 years) used a 0.3% estriol cream. The ointment, at a dose of 1 g, was applied daily for 6 months on the face and neck using an applicator. To investigate for possible systemic hormonal side effects,<sup>19</sup> venous blood was sampled at 8 AM before treatment and then at monthly intervals for determination of follicle-stimulating hormone (FSH), prolactin (PRL), and estradiol (E<sub>2</sub>) by standard radioimmunoassay (RIA) methods.

Monitoring of the condition of the skin before and at the end of the treatment included clinical controls, skin profilometry, corneometry, and, in 10 cases, skin biopsies for immunohistochemical investigation of the collagen types. Ten women who had agreed to a skin biopsy voluntarily, confirmed this by giving written informed consent. For the clinical evaluation, wrinkling, skin elasticity, pore size, and skin moisture were assessed according to an individual evaluation scheme.

**Skin Profilometry:** Wrinkles were measured and evaluated in patients of the estradiol and the estriol groups. With the method, five fold measurements of the profile of replicas of identical corresponding wrinkles are performed with the Hommelteste T 2000 (Hommelwerke, Schweningen,

Germany). The material for the replicas was Provil LCD (Bayer Dental), a rapidly drying material on a silicone basis. In brief, a microsensor scans the print under a defined angle and at constant speed. The movements are transformed into units of elastic tension. The electric impulses are magnified and digitized. The representative parameter RzD is the mean roughness depth of a single roughness depth out of five measurement distances. The method has been described in detail.<sup>20</sup>

**Corneometry:** The hydration of the stratum corneum was determined by corneometry between 11 and noon at a room temperature of 21°C and a humidity of 40 to 45%. The instrument used was the corneometer CM 420 (Schwarzaupt Medizintechnik, Cologne, Germany), which acts by measuring capacitance with a plane capacitor. Data are displayed numerically. One unit represents 0.02 ng per cm<sup>2</sup> water content of stratum corneum corresponding to a level of 20 nm.<sup>21</sup>

**Immunohistochemistry:** Biopsy specimens were fixed routinely in 10% buffered formaldehyde and embedded in paraffin. Paraffin sections, 4 µm thick, were cut and subjected to immunocytochemistry according to the ABC-technique. Primary antibodies used were directed against collagen I (AB 745, Chemicon, Temecula, CA), diluted 1:800, and against collagen III (PS 49, Monosan, Uden, The Netherlands), diluted 1:10. The secondary antibody consisted of biotinylated antirabbit IgG and was followed by the ABC solution (both from Vectastain, Burlingame, CA). All incubations were performed for 30 minutes at room temperature. For development of the peroxidase reaction, diaminobenzidine tetrahydrochloride (DAB) was used. The preparations were evaluated semiquantitatively by estimating the degree of the immunohistochemical staining.

## RESULTS

At the end of treatment, marked improvement of skin aging symptoms was noted. The clinical findings were confirmed by the measurement data. The Wilcoxon-test was used for statistical analysis. No significant differences between E<sub>2</sub> and FSH levels were found between pretreatment and final values. Prolactin showed a highly significant increase in the estradiol, and a significant increase in the estriol groups (Table 1), but PRL

Table 1. Initial and Final Hormone Levels in Perimenopausal Women Treated with Topical Estrogens

	Estradiol Group					Estriol Group				
	N	Initial Level	Final level	P	Normal Range	N	Initial Level	Final Level	P	
FSH (mU/mL)	24	55.9 ± 38.9*	57.0 ± 41.7	P > .05 NS	30–120	22	66.9 ± 33.2	72.5 ± 30.0	> .05 NS	
PRL (ng/mL)	24	5.1 ± 2.0	8.3 ± 4.4	P = .0005 HS	2–25	21	6.5 ± 4.1	8.4 ± 3.7	P = .029 S	
E <sub>2</sub> (pg/mL)	18	60.0 ± 109.5	78.1 ± 129.5	P > .05 NS	0–55	21	23.4 ± 19.4	22.9 ± 29.8	P > .05 NS	

\*Values are mean ± standard deviation.

N = number of patients; E<sub>2</sub> = estradiol; FSH = follicle stimulating hormone; PRL = prolactin; NS = not significant; S = significant; HS = highly significant.

**Table 2. Grading of Clinical Effects of Topical Estrogen Treatment on Facial Skin**

*	Minor effects consisting of increased vascularization and moisture of skin
**	Minor decrease of wrinkle depth or improvement of firmness and elasticity of skin
***	Clear improvement of wrinkles, evident by monitoring and photodocumentation
****	Significant decrease of wrinkle depth

levels stayed within the normal range in both treatment groups.

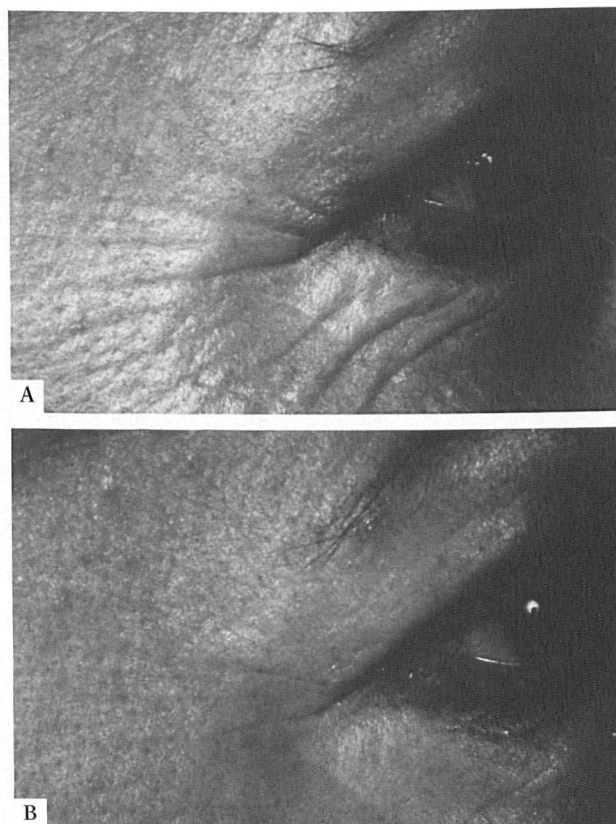
The clinical improvement of specific skin parameters was evaluated according to a personal evaluation scheme (Table 2); it was seen after 9 to 19 weeks in the estradiol and after 7 to 17 weeks in the estriol group. Improvement of vascularization, elasticity, and skin moisture ranged between 100% and 61% in the two groups (Table 1).

Wrinkle measurements by profilometry showed significant decreases in the estradiol and highly significant decreases in the estriol group (Figs. 1A, 1B, Table 3). Skin moisture by corneometry showed insignificant increases in both groups (Table 3). For immunohistochemistry, the specific staining was localized to the dermal connective tissue.

As demonstrated in Figure 2A, a difference in immunohistochemical staining for collagen III could be demonstrated in biopsies taken before and after treatment. In biopsy specimens after treatment, there appeared to be a more intense color reaction as compared to biopsies taken before treatment, indicating an increase in collagen III after treatment (Fig. 2B). No clear difference in staining for collagen I could be demonstrated before and after therapy (Table 4).

### Side Effects

The side effects were less in the estriol than in the estradiol group. Breast tension, naturally occurring in periods of hormonal changes, was noted by 12 of 30 patients treated with estriol compared to 7 of 28 patients of the estradiol group. One patient treated with



**Figure 1.** A, Wrinkles prior to estriol treatment. B, Wrinkles at the end of a 6-month treatment period with topical 0.3% estriol.

estriol complained of itching, one patient treated with estradiol complained of local reddening of the face. Of the 28 women treated with estradiol, three observed increased facial pigmentation.

### DISCUSSION

Estrogen compounds were shown to be effective in the treatment of skin aging symptoms of perimenopausal women. Both estradiol and estriol, at the concentrations used, exhibited comparable results. In a previous pilot study we had shown the lack of systemic hormon-

**Table 3. Clinical Evaluation of Symptoms of Aging in 58 Women Treated with Topical Estradiol Compared to Estriol**

	<i>Estradiol 0.01% (N = 30)</i>		<i>Estriol 0.3% (N = 28)</i>	
	<i>Incidence of Improvement (%)</i>	<i>Onset of Effects in Weeks after Start of Treatment (Mean)</i>	<i>Incidence of Improvement (%)</i>	<i>Onset of Effects in Weeks after Start of Treatment (Mean)</i>
Vascularization	100	9	96	7
Skin elasticity and firmness	100	13	96	11
Moisture	100	9	96	8
Wrinkle depth	87	16	89	17
Pore size	73	19	61	16

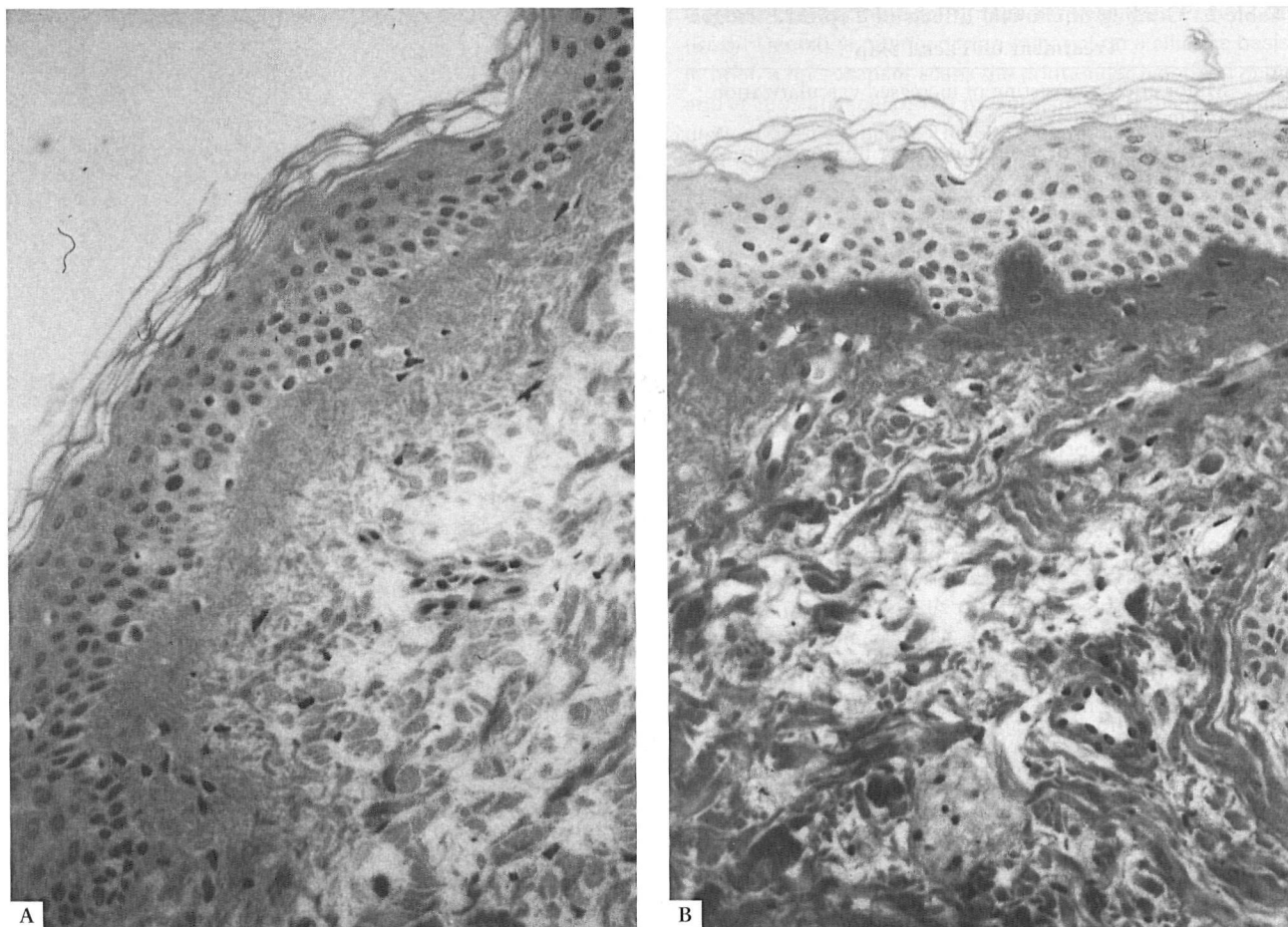


Figure 2. A, Collagen III prior to treatment with topical estriol. B, Increase of collagen III at the end of treatment with topical estriol. (original magnification  $\times 180$ )

al side effects by gynecologic monitoring with vaginal smears<sup>22</sup> and by the lack of significant differences between initial and final serum levels of hormones.<sup>17</sup> The latter was confirmed in the present study only for E2 and FSH. The increases of PRL observed in both treatment groups may be indicative of increased estrogenic actions through hypophyseal feedback. In contrast, estradiol levels showed no significant changes.

Estradiol and estriol are both topically active substances, used by gynecologists against vulvar atrophy and pruritus.<sup>23</sup> Estradiol may cause systemic side effects

on the endometrium dependent on the concentration used. In contrast, estriol is an estrogen the prevalent effects of which are displayed at the vaginal epithelium, but that has no systemic side effects on the plaster epithelium of the endometrium.<sup>24</sup> Furthermore, estriol is the biologically weaker estrogen,<sup>25</sup> and mainly epidermotropic properties of estriol have been described in the skin.<sup>26</sup>

The present data indicate for the first time that estriol exhibits also significant effects on collagen. Both estriol and estradiol treatment induced significant increases of collagen fibers and striking increases of col-

Table 4. Initial and Final Measurement Parameters (Mean  $\pm$  SD) of Corneometry and Profilometry in Both Patient Groups

<i>Estrogen Used</i>	<i>(N)</i>	<i>Initial Value</i>	<i>Final Value</i>	<i>P</i>
Corneometry (Units)				
Estradiol	20	66 $\pm$ 27	79 $\pm$ 14	P > .05 (NS)
Estriol	20	66 $\pm$ 26	78 $\pm$ 16	P > .05 (NS)
Profilometry (RZ-D in $\mu$ m)				
Estradiol	21	50 $\pm$ 18	41 $\pm$ 16	P = .002 (S)
Estriol	22	48 $\pm$ 20	38 $\pm$ 22	P = .0005 (HS)

Unit = ng/cm<sup>2</sup> water content of stratum corneum.

RZ-D = arithmetic mean of the maximal depths of roughness out of five adjoining distances measured.



Table 5. Distribution of Type I and Type III Collagen in the Dermis and at the Basal Membrane before and at the End of Treatment with Topical Estrogen in 10 Women

	Collagen I				Collagen III	
	Pretreatment Dermis	BM*	End of Treatment Dermis	BM	Pretreatment Dermis	End of Treatment Dermis
Estradiol	+	±	+	+	+	+++
	+	+	+	++	+	+++
	++	+	++	++	++	+++
	±	±	+	±	+	++
Estriol	+	+	++	++	+	+++
	±	±	+	+	++	+++
	+	+	±	±	++	++
	+	±	++	++	+	+++
	+	+	+	++	+	+++
	+	±	+	++	+	+++

\*BM = basal membrane.

lagen III. These findings support the role that estrogens play in the dermis and may serve as an explanation for the clinical observations of increased firmness and significantly less wrinkling during treatment. Both types of collagen change during the aging process. Type I collagen represents the predominant collagen type in adult human skin,<sup>27</sup> whereas type III collagen, also widely distributed throughout the body, predominates in tissues of fetuses.<sup>28</sup> For the first time, increases of mainly type III collagen indicate distinct modulatory effects of estrogen on collagen tissue.

The positive effects of estrogens on the water content of the skin, that were observed in all patients, may be due to dermal and epidermal components. The estrogen-stimulated increases of acid mucopolysaccharides and of hyaluronic acid<sup>14,15</sup> contribute to an increase water content in the dermis. The increased epidermal water content may be due to increased epidermal skin thickness<sup>29,30</sup> with subsequently elevated amounts of a natural moisturizing factor.

The present study supports the effectiveness of estrogen compounds in the treatment of skin aging in perimenopausal women. Both, estradiol and estriol showed good and comparable effects in the concentrations used and a lack of systemic side effects when applied only to the face and neck. Obviously, no predictions about systemic side effects can be made about the same hormonal substances under different conditions (e.g., increased concentrations or size of application field). Dose-finding studies in both directions are therefore absolutely necessary, in order to find the minimum concentration of an estrogen compound that combines the best possible clinical effects without systemic hormonal side effects. In general, estriol seems to be the preferable estrogen for topical use. Lack of systemic side effects and promising local effects after external use suggest that estriol will gain importance for topical use in dermatology in the future.

## CONCLUSIONS

By considering the results of topical estrogen treatment in skin aging in women, a better insight can be gained on the hormonal aspects of endogenous aging of the skin. Various structures involved in skin aging are under hormonal control. If decreased estrogen levels contribute to decreased functions of the skin, local estrogen treatment of the skin would in turn represent a local hormone substitution therapy of the skin. So far, estrogen compounds and, in particular, estriol represent a new and promising therapeutic approach towards skin aging in perimenopausal women.

## REFERENCES

1. Kligman AM, Grove GL, Hirose R, Leyden J. Topical tretinoin for photoaged skin. *J Am Acad Dermatol* 1986; 15:836-859.
2. Weiss JW, Ellis CN, Headington JT, Vorhees JJ. Topical tretinoin in the treatment of aging skin. *J Am Acad Dermatol* 1988; 19:169-175.
3. Tong PHS, Horowitz MS, Wheller LA. Transretinoic acid enhances the growth responses of epidermal keratinocytes to epidermal growth factor and transforming growth factor beta. *J Invest Dermatol* 1990; 87:663-667.
4. Harper RA, Burgoon T. Differential effects of retinoic acid on the growth of normal fibroblast-like cells *in vitro* from human, swine and rabbit skin. *Cell Biol Int Rep* 1982; 6:163-170.
5. Kligman LH, Kligman AM. Skin changes in photoaging: characteristics, prevention and repair. In: Balin AK, Kligman AM, eds. *Aging and the skin*. New York: Raven Press, 1989:331-346.
6. Artner J, Gitsch E. Über Lokalwirkungen von Östriol. *Geburtshilfe und Frauenheilkd* 1959; 19:812-819.
7. Boselli F, Volpe A, Genazzani AR. Topical therapy: estriol vaginal cream in postmenopausal women. In: Genazzani AR, Volpe A, Facchinetti F, eds. *Gynaecolog-*

- ical endocrinology. Carnforth: Parthenon Publishing, 687–694.
8. Riedel M, Rafflenbeul W, Lichtlen P. Ovarian sex steroids and atherosclerosis. *Clin Invest* 1993; 71: 406–412.
  9. Falkeborn M, Persson I, Adami HO, et al. The risk of acute myocardial infarction after oestrogen and oestrogen and progesterone replacement. *Br J Obstet Gynecol* 1992; 99:821–828.
  10. Gallagher JC, Nordin BEC. Effects of oestrogen and progesterone therapy on calcium metabolism in postmenopausal women. In: *Frontiers of Hormone Research* 3. Basel: Karger :150–176.
  11. Schmidt JB, Spona J. Östrogen- und Androgenrezeptoren bei Patienten mit Akne vulgaris. *Arch Dermatol Res* 1980; 268:207–215.
  12. Schmidt JB, Lindmaier A, Spona J. Hormone receptors in pubic skin of premenopausal and postmenopausal females. *Gynecol Obstet Invest* 1990; 30:97–100.
  13. Punnonen R, Vaajalahti P, Teisala K. Local oestriol treatment improves the structure of elastic fibres in the skin of postmenopausal women. *Ann Chir Gynaecol (Suppl)* 1987; 202:39–41.
  14. Grosman N, Hridbey E, Schon J. The effect of oestrogenic treatment on the acid mucopolysaccharide pattern in skin of mice. *Acta Pharmacol Toxicol* 1971; 30:458–464.
  15. Grosman N. Studies on the hyaluronic acid protein complex the molecular size of hyaluronic acid and the exchangeability of chloride in skin of mice before and after oestrogen treatment. *Acta Pharmacol Toxicol* 1973; 33:201–208.
  16. Luisi M, Franchi F, Kicovic PM. A group-comparative study of effects of Ovestin cream versus Premarin cream in post-menopausal women with vaginal atrophy. *Maturitas* 1980; 2:311–319.
  17. Schmidt JB, Binder M, Macheiner W, et al. Treatment of skin aging symptoms in perimenopausal females with estrogen compounds—a pilot study. *Maturitas* 1994; 20:25–30.
  18. Schmidt JB, Binder M, Macheiner W, Bieglmayer CH. New treatment of atrophic acne-scars by iontophoresis with estriol and tretinoin—a pilot study. *Int J Dermatol* 1995; 34:53–57.
  19. Reinthaller A, Kirchheimer JC, Deutinger J, et al. Plasminogen activators, plasminogen activator inhibitor and fibronectin in human granulosa cells and follicular fluid related to oocyte maturation and intrafollicular gonadotropin levels. *Fertil Steril* 1990; 54:1045–1051.
  20. Binder M, Macheiner W, Schmidt JB. Die Profilometrie—eine Dokumentationsmethode der Hautstruktur. *Hautarzt* 1994; 45:546–550.
  21. Schmidt JB, Hobisch G, Lindmaier A. Epidermal moisture and skin surface lipids throughout life as parameters for cosmetic care. *Appl Cosmetol* 1990; 8:17–22.
  22. Kainz C, Gitsch G, Stani J, et al. When applied to facial skin, does estrogen ointment have systemic effects? *Arch Gynecol Obstet* 1993; 253:71–74.
  23. Lauritzen C. Erfahrungen mit einer Östriol-Vaginalcreme. *Therapie Gegenw* 1979; 118:567–577.
  24. Tzingouinis VA, Aksu MF, Greenblatt RB. The significance of oestriol in the management of the post menopause. *Acta Endocrinol Suppl* 1980; 233:45–50.
  25. Frost P, Weinstein GD, Hsia SL. Metabolism of oestradiol and oestrogen in human skin. *J Invest Dermatol* 1966; 46:584–585.
  26. Wendker H, Schaefer H, Zesch A. Penetrationskinetik und Verteilung lokal applizierter Östrogene. *Arch Dermatol Res* 1976; 256:67–74.
  27. Epstein EH, Munderloh NH. Isolation and characterization of CNBr peptides of human (alpha 1 [III] 3) collagen and tissue distribution of (alpha 1 [I] 2), alpha 2 and (alpha 1 [III] 3) collagens. *J Biol Chem* 1975; 250: 9304–9312.
  28. Epstein EH. (Alpha 1 [3]) human skin collagen. Release by pepsin digestion and preponderance in fetal life. *J Biol Chem* 1974; 249:3225–3231.
  29. Rauramo L, Punnonen R. Wirkungen von Kastration und Östrogentherapie auf die Haut der Frau. *Therap Umschau* 1974; 31:173–175.
  30. Brincat M, Moniz CJ, Studd JW. Long-term effects of the menopause and sex hormones on skin thickness. *Br J Obstet Gynaecol* 1985; 92:256–259.

## Comparative Medical Research

Legions of aquatic animals—whose biodiversity is virtually untapped in biomedical research—have been enlisted in the war against human disease. The zebrafish is an important new model for developing transgenic techniques, for genetic and embryological studies, and for spawning a growing “zebrafish community” of researchers. National Center for Research Resources (NCRR) also supports studies of abalone, cephalopods, clams, hydra, lobster, sea slugs, sea squirts, sea urchins, and trout.

Nonhuman primates continue to be widely-used animal models. Researchers at one of NCRR's seven Regional Primate Research Centers have isolated the first embryonic stem cells produced from rhesus monkeys and marmosets, opening the way for transgenesis and gene therapy in primate systems within the next five years. From Vaitukaitis JL. *Looking ahead at comparative medicine research. Comparative Pathol Bull* 1995; XXVII(2):1.

This document is a scanned copy of a printed document. No warranty is given about the accuracy of the copy. Users should refer to the original published version of the material.